

Multimodality assessment of hepatic fibrosis: Ranked paired reading and artificial intelligence identifies fibrosis improvement with Aramchol missed by conventional staging

Author List

V. Ratziu¹, Y. Yilmaz², D. Lazas³, S.L. Friedman⁴, C. Lackner⁵, C. Behling⁶, OW. Cummings⁷, Li Chen⁸, M. Petitjean⁸, Y. Gilgun-Sherki⁹, S. Kadosh¹⁰, and A. J. Sanyal¹¹

Affiliations

¹Sorbonne Université, Institute for Cardiometabolism and Nutrition (ICAN) and Hôpital Pitié- Salpêtrière, INSERM UMRS 1138 CRC, Paris, France; ²Liver Research Unit, Institute of Gastroenterology, Marmara University, and Department of Gastroenterology, School of Medicine, Marmara University, Istanbul, Turkey; ³ObjectiveGI, Inc., Nashville, TN, USA; ⁴Division of Liver Diseases, Icahn School of Medicine at Mount Sinai, New York, NY, USA; ⁵Institute of Pathology, Medical University of Graz, Graz, Austria; ⁶Department of Pathology, Sharp Health System, San Diego, CA, USA; ⁷Department of Pathology and Laboratory Medicine, Indiana University School of Medicine, Indianapolis, IN 46202, United States; ⁸Pharmanest, Inc. Princeton, NJ, USA; ⁹Galmed pharmaceuticals Ltd. Tel-Aviv Israel; ¹⁰Stateexcellence Ltd. Israel; ¹¹Department of Gastroenterology, Virginia Commonwealth University, Richmond, VA, USA.

Background and Aims

Aramchol is a partial inhibitor of hepatic stearoyl-CoA desaturase (SCD1) with direct anti-fibrotic activity demonstrated in pre-clinical models¹. A phase 2b, placebo-controlled study (NCT02279524), in patients with biopsy confirmed NASH demonstrated the potential of 52 weeks treatment with Aramchol 600mg once daily (QD) to improved liver histology and reduce liver fat, liver enzymes and HbA1C2.

The ARMOR study is a Phase 3, multinational, randomized, double-blind, placebo-controlled trial assessing Aramchol 300mg twice daily (BID) in subjects with NASH. (NCT04104321). An Open-Label Part was added to the study, designed to provide data on the new dosing regimen with the higher exposure as well as characterize the kinetics of histological outcomes (see Figure 1).

Acknowledging the complexity, variability and moderate reproducibility in liver pathology reading, the Open Label part was also used to further assess different methodologies that may support and improve fibrosis scoring.

Methods

157 patients with NASH and fibrosis documented by biopsy were randomized 1:1:1 to receive Aramchol 300 mg BID and underwent a control biopsy at weeks 24, 48 or 72. Data is available from the first 51 patients with a post-baseline biopsy.

All slides were assessed for fibrosis using 3 histopathological methodologies:

- The NASH CRN staging: staging was initially performed individually by the 3 independent pathologists, followed by a consensus reading by the committee
- A ranked assessment: The same central committee performed a ranked assessment (improvement/worsened/stable) of paired biopsies, scrambled and blinded to sequence
- Artificial Intelligence: The same slides were scanned and read using FibroNest™, a quantitative Digital Pathology image analysis and AI automated, full tissue method providing a continuous phenotypic Fibrosis Composite Severity (FCS) score that ranges from 1 to 10 for the full spectrum of fibrosis severity observed in the liver. This allows identifying fibrosis improvement that may be missed by staging methods as well as statistical quantification of change from baseline. A 0.3 reduction in FCS (4-fold higher than the analytical variability) identified any reduction in fibrosis; a 25% relative decline in FCS, a strong reduction in fibrosis.

Results

Post-baseline biopsies were performed in 51 patients (28 and 23 pts at <48 weeks and ≥ 48 weeks, respectively) that received Aramchol. At baseline, mean age was 59.7; 80% were females; 86% White; mean weight 88.8, mean BMI 33.2 kg/m²; 32 patients had stage 3 fibrosis; 11 stage 2, and 8 stage 1; Mean FCS was 5.0 (see Table 1).

A greater fibrosis improvement with longer duration of therapy for both conventional histology and digital pathology readings was demonstrated (see Table 2). For all methods, a treatment effect was larger at ≥48 compared to <48 weeks. At week 48 or more, fibrosis improvement was identified in 39%, 61% and 100% of patients according to NASH CRN, paired and AI, respectively using a FCS absolute reduction of 0.3 (see Table 2 and Figure 2). Mean FCS reduction was -0.5385 (p=0.02) at <Wk48 and -1.7248 (p<0.0001) at ≥Wk 48. AI evaluation was consistent with paired reading in 22/38 (57.9%) of the pts with fibrosis improvement. When analyzed by AI, 18/25 pts with unchanged NASH CRN stages had any fibrosis response, including 9 with a strong response. Similarly, 14/18 pts with stable ranking had a fibrosis response, including 6 with a strong reduction. No pts with worse CRN stages or worsening ranking had a strong AI fibrosis reduction.

Figures and Tables

Figure 1. Study Design

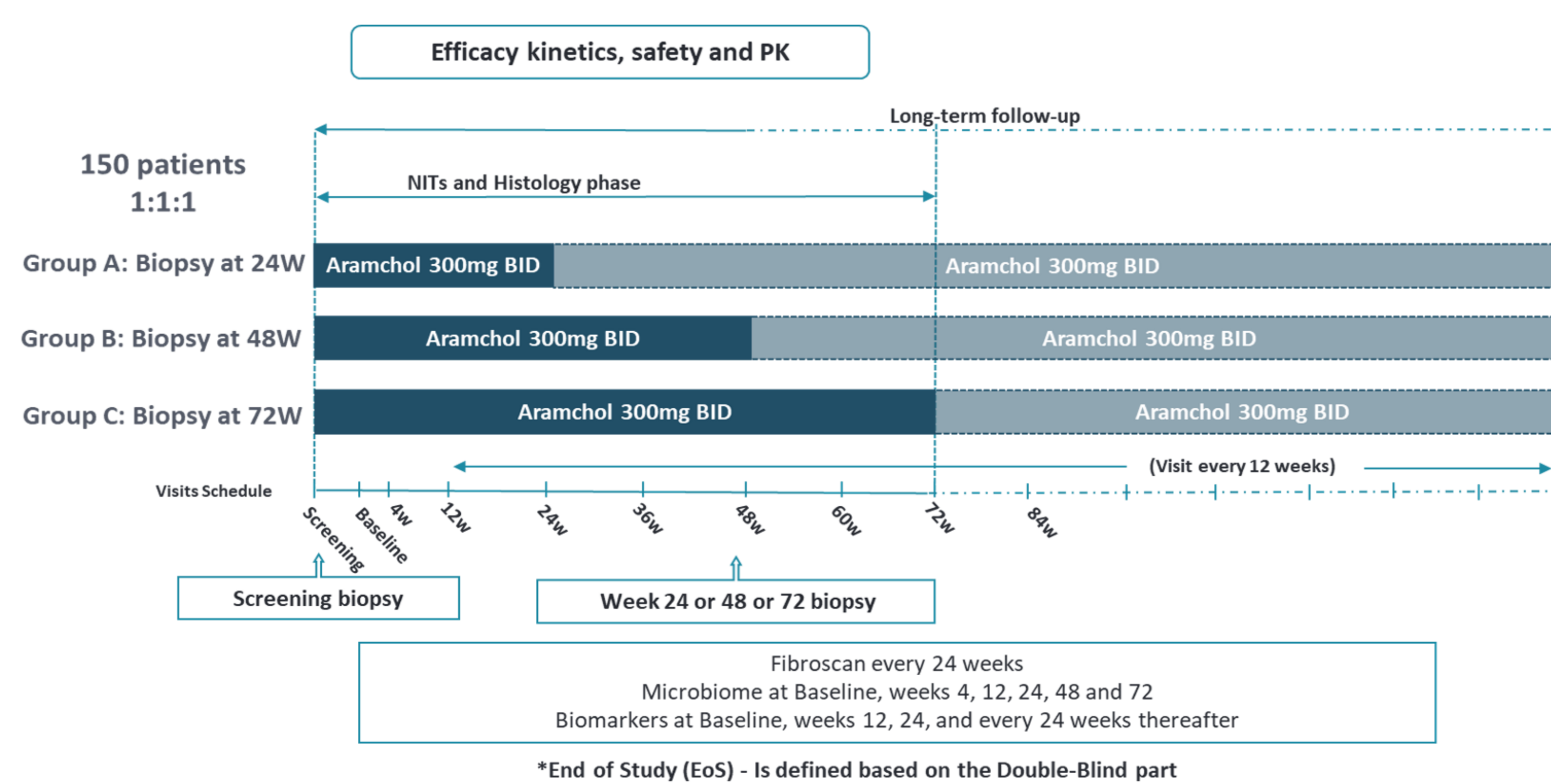


Figure 2. Proportion of Patients with Fibrosis Improvement for Each Reading Methodology after ≥48 weeks of Treatment with Aramchol

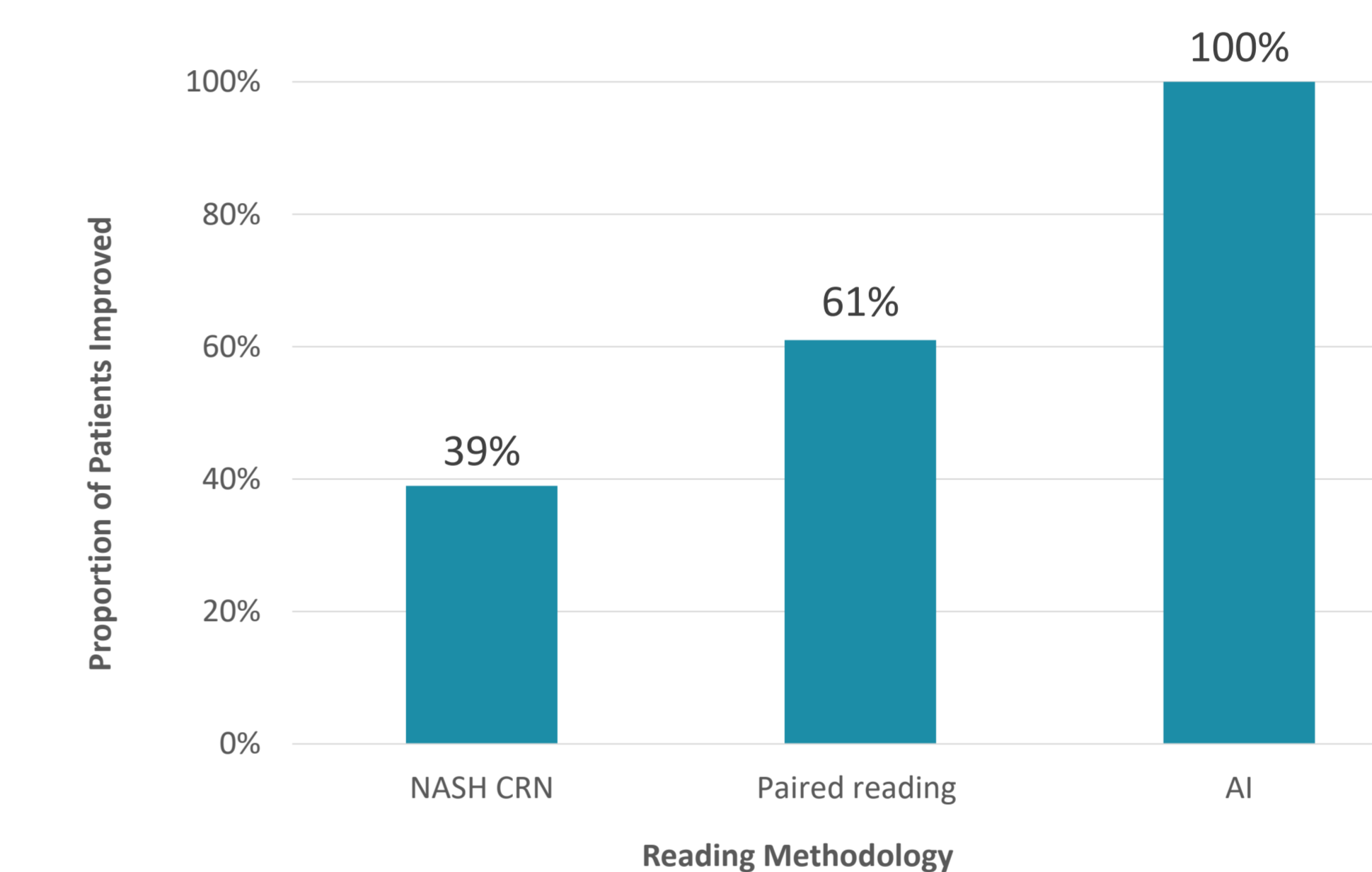


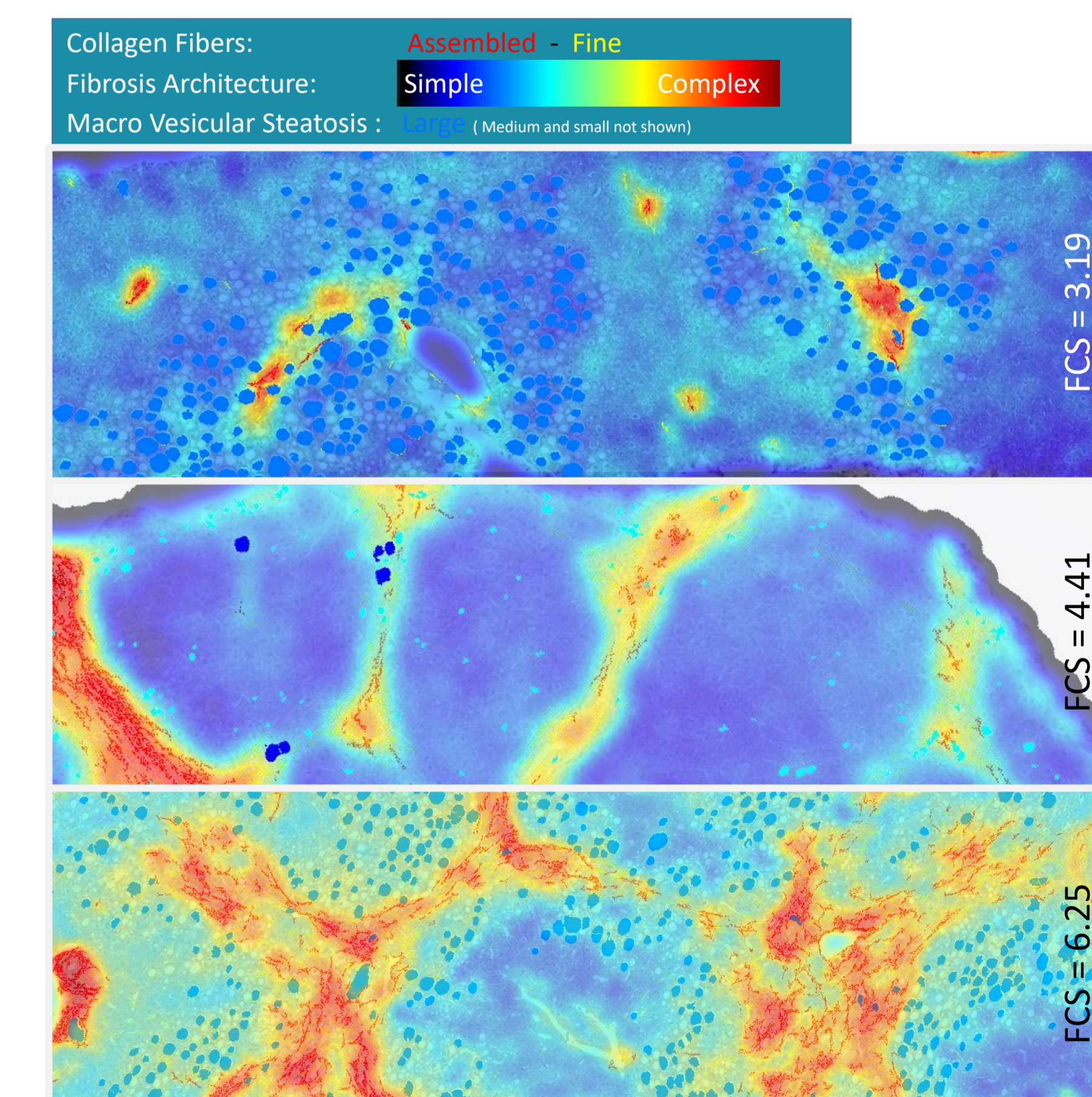
Table 1. Baseline Characteristics

| ARMOR Study | All Subjects (N=51) |
|--------------------------------------|---------------------|
| Female | 41 (80.4%) |
| Age years (mean ± SD) | 59.7 ± 8.9 |
| Weight (kg) (mean ± SD) | 88.8 ± 13.9 |
| BMI (kg/m ²) (mean ± SD) | 33.2 ± 4.3 |
| Race | White 44 (86.3%) |
| | Asians 6 (11.8) |
| | Other 1 (2.0%) |
| Fibrosis stage | F1 8 (15.7%) |
| | F2 11 (21.6%) |
| | F3 32 (62.7%) |
| FCS (mean ± SD) | 5.0 ± 1.05 |

Table 2. Biopsy Results Using 3 Histopathological Reading Methodologies

| Biopsy methodology | Post-BL Biopsy at <W48 weeks | | Post-BL Biopsy at ≥ W48 | |
|--|------------------------------|-------|-------------------------|-------|
| | N | % | N | % |
| All | 28 | 100% | 23 | 100% |
| Fibrosis Improvement (1 point or more) based on NASH CRN | 7 | 25% | 9 | 39% |
| Fibrosis Improvement (Paired reading ranked assessment) based on comparing individual patients slides | 12 | 43% | 14 | 61% |
| Subject Fibrosis Response (AI reading) using Fibronest's Phenotypic FCS (A responder is defined by an absolute reduction of > 0.3) | 15 | 54% | 23 | 100% |
| Subject Fibrosis Response (AI reading) using Fibronest's Phenotypic FCS (A responder is defined by a relative reduction of > 25%) | 6 | 21.4% | 15 | 65.2% |

Augmented Pathology Images



Conclusion

Aramchol resulted in a high proportion of fibrosis improvement using three separate biopsy reading methodologies, with a larger treatment effect with longer duration of therapy. Both ranked assessments and AI evaluations identified more subjects with fibrosis improvement, indicating greater sensitivity to change vs categorical scoring. Digital pathology quantification by AI reveals a high level of fibrosis improvement that would have been missed by conventional histological measurements. AI technologies are promising for the detection of fibrosis changes in future clinical trials.

¹ Bhattacharya et al. Aramchol downregulates stearoyl CoA-desaturase 1 in hepatic stellate cells to attenuate cellular fibrogenesis. *JHEP Rep* 3, 100237 [2021] 28 Jan. 2021