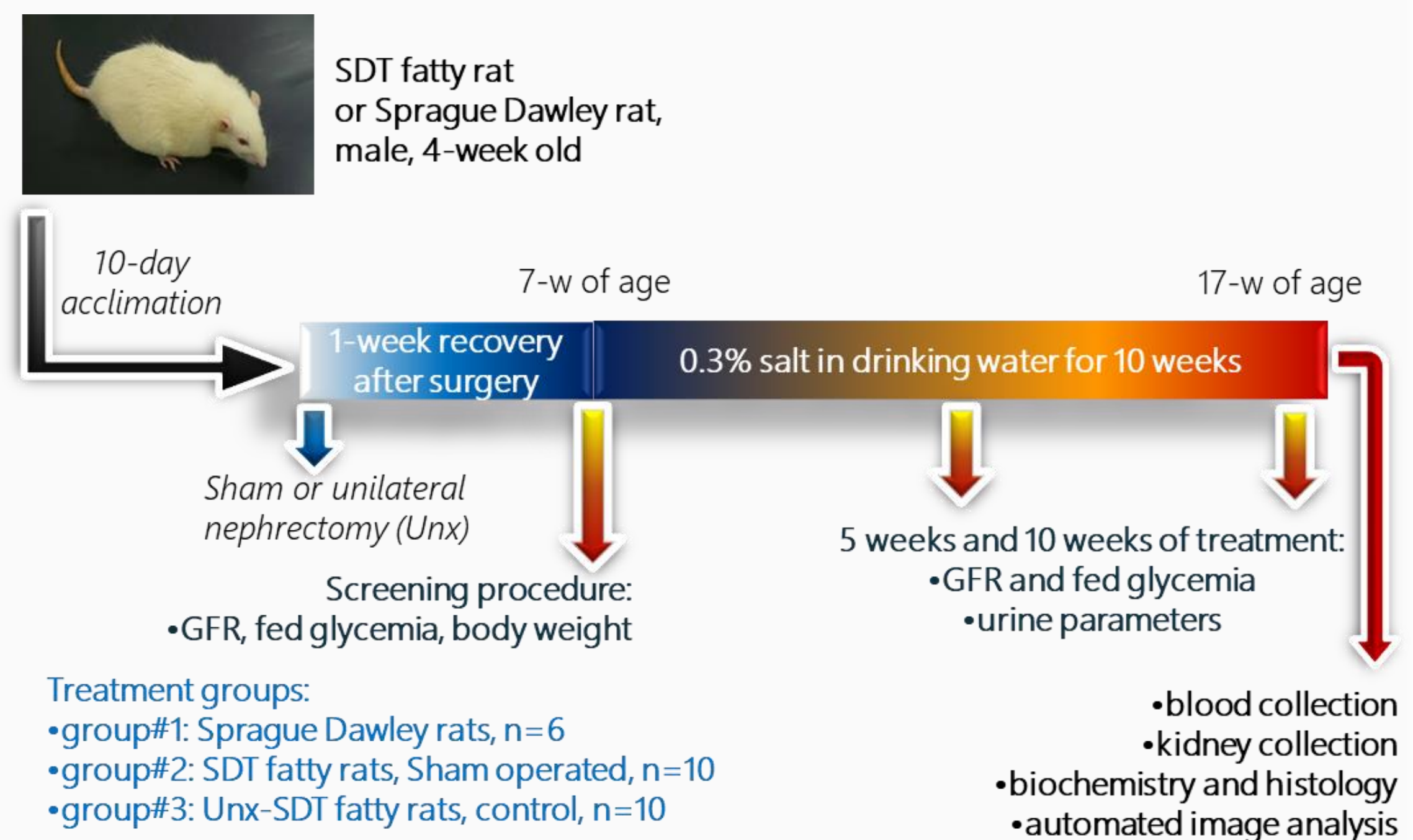


## BACKGROUND:

The Spontaneously Diabetic Torii (SDT) fatty rat is a relevant type 2 diabetic model to evaluate drugs targeting diabetic nephropathy. To further optimize the model for drug efficacy studies, we here tested the effects of unilateral nephrectomy and salt supplemented diet on kidney function and histology. Using quantitative image analysis, we also assessed podocyte foot process morphology and kidney fibrosis.

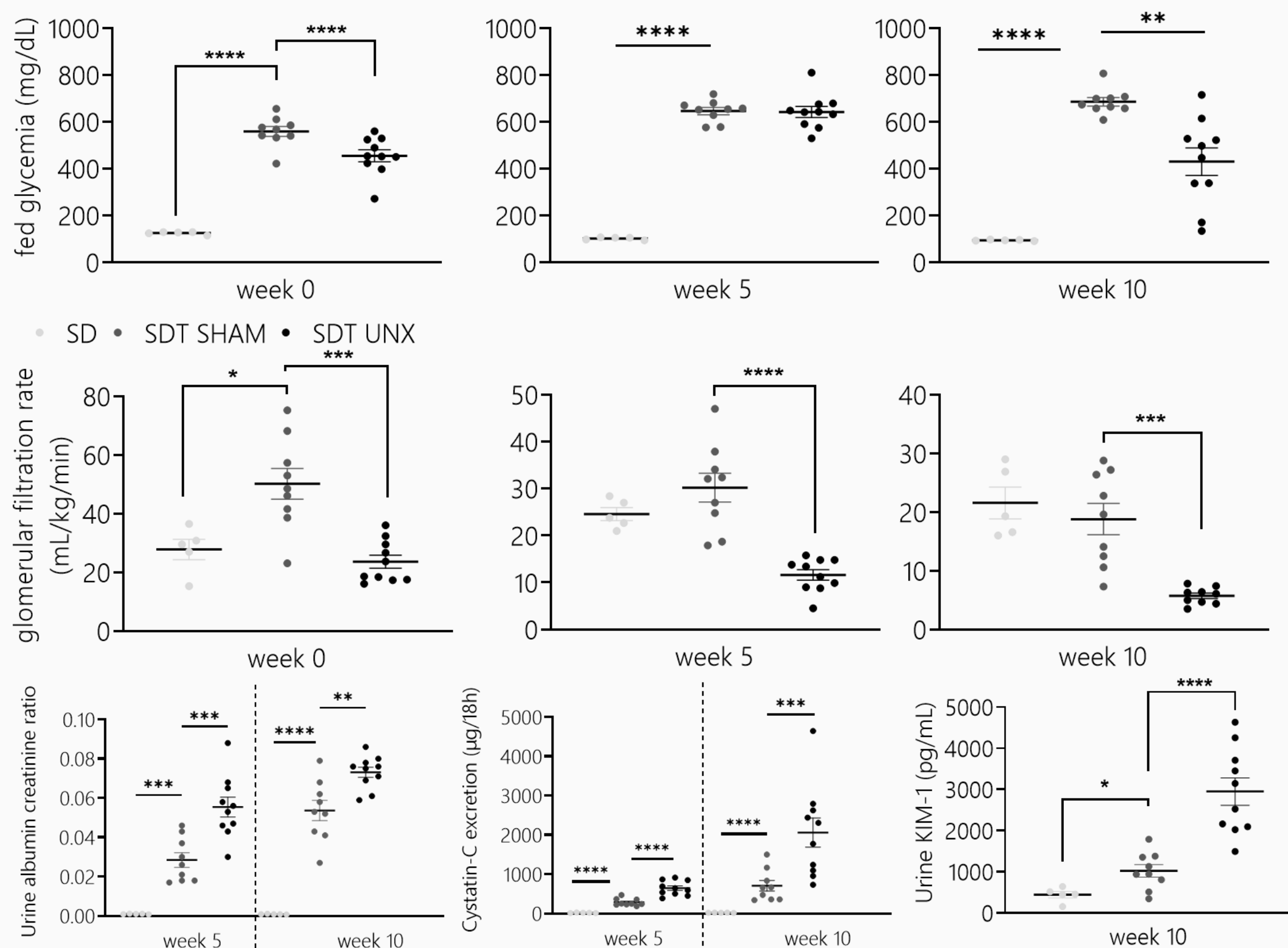
## METHODS:

Sham operation or unilateral nephrectomy (Unx) were performed on male, 6-week-old, SDT fatty rats. After surgery recovery, Sham and Unx SDT fatty rats were maintained on a 0.3% salt diet for 10 weeks. A group of Sprague Dawley (SD) rats was included as a negative control. Glomerular Filtration Rate (GFR) and urine parameters were measured at baseline, 5 weeks, and 10 weeks. Kidneys were collected at 10 weeks for histology and quantitative image analysis, including the Podocyte Exact Morphology Measurement Procedure (PEMP) and quantitative digital pathology of kidney fibrosis (FibroNest platform).



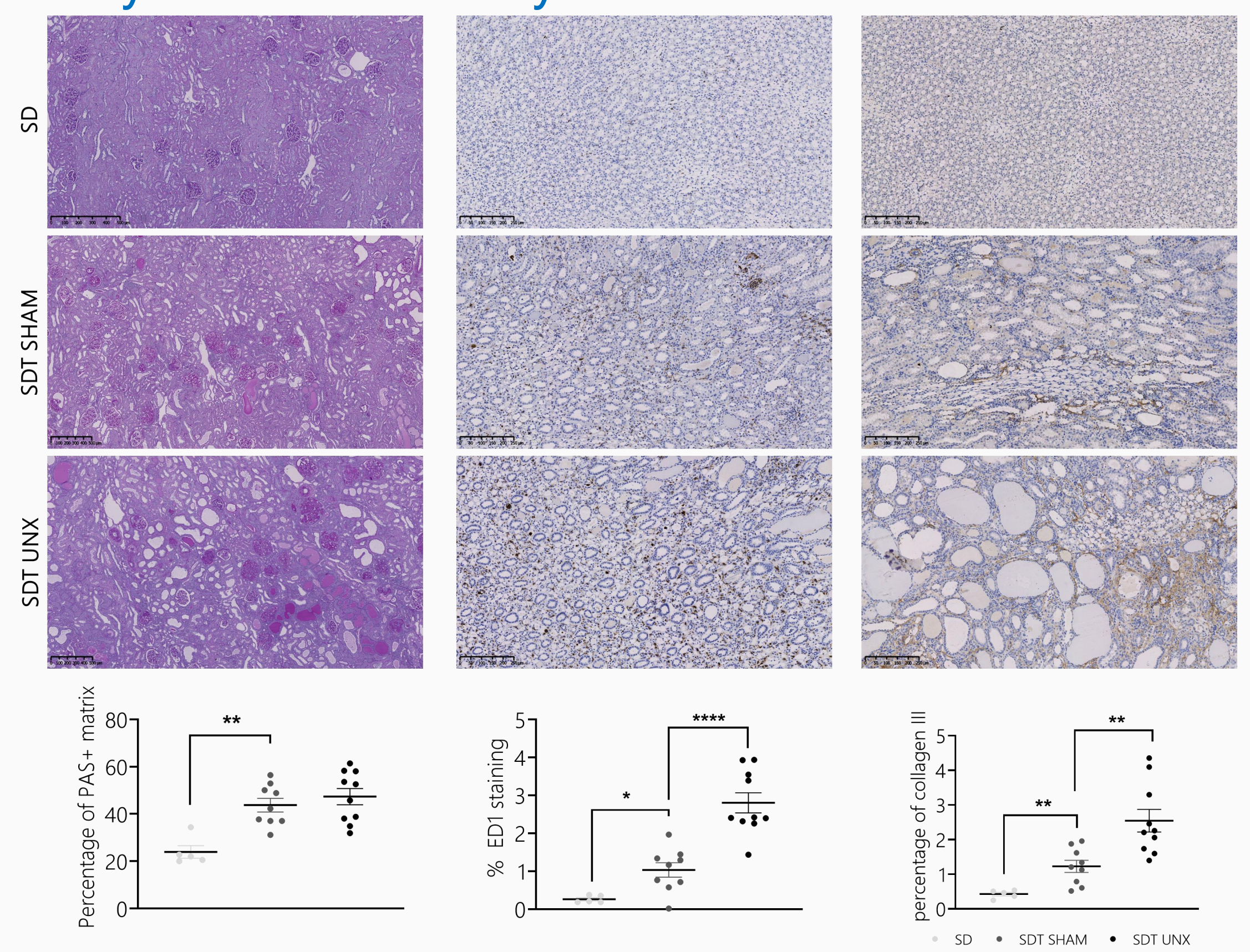
## RESULTS:

### 1 Unilateral nephrectomy with salt supplementation leads to kidney dysfunction in SDT fatty rats



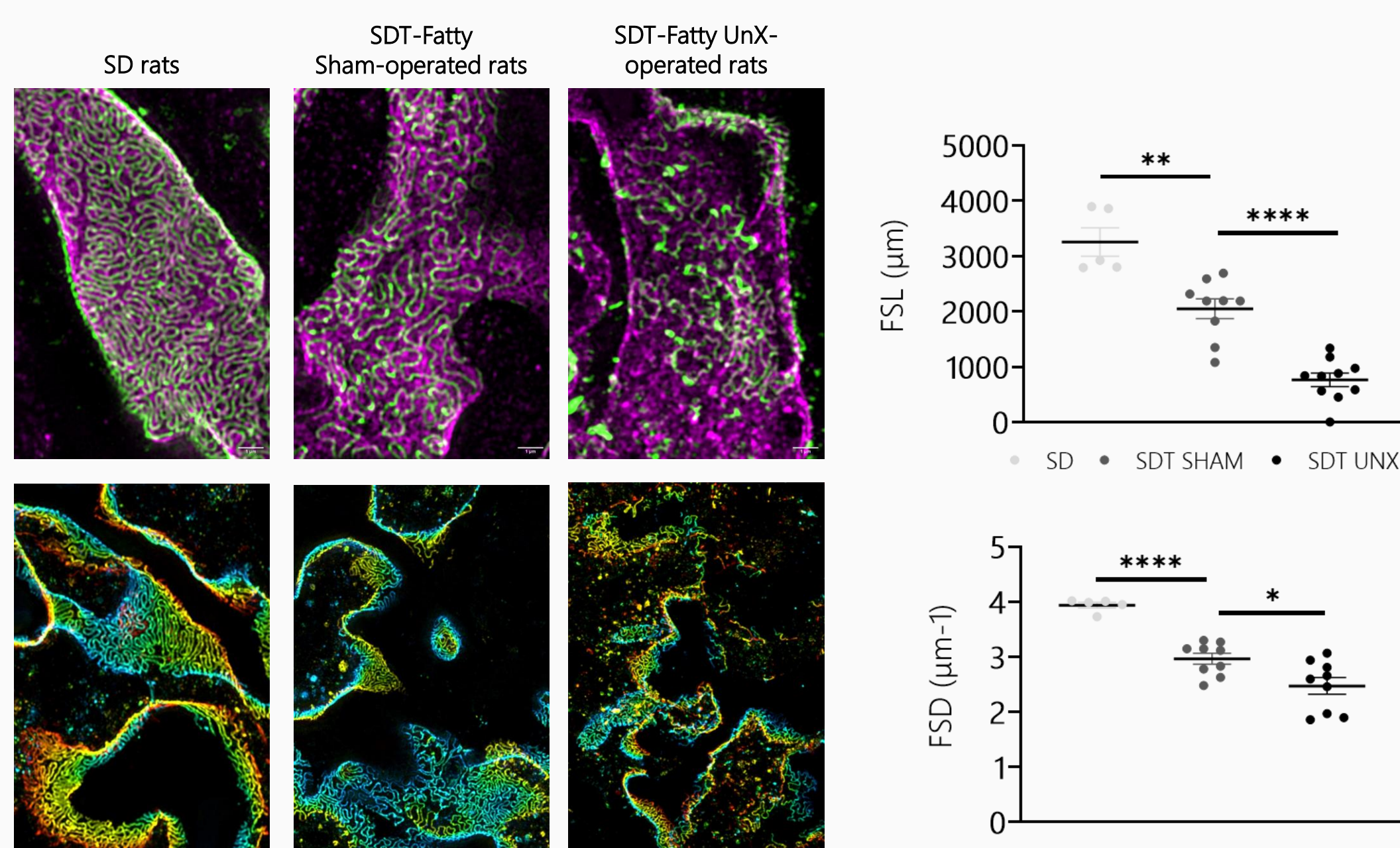
Fed glycemia (upper panel), glomerular filtration rate (middle panel), urine albumin/creatinine ratio, cystatin-C and KIM-1 excretion (lower panel) in SD rats, sham or Unx SDT fatty rats. \* $p < 0.05$ , \*\* $p < 0.01$ , \*\*\* $p < 0.001$  and \*\*\*\* $p < 0.0001$

### 2 Unilateral nephrectomy with salt supplementation aggravates kidney lesions in SDT fatty rats



Representative pictures and % labelling for Periodic Acid Schiff (PAS) staining (A), ED1 (B) and Collagen III (C) immunostaining in SD rats, sham or Unx SDT fatty rats. \* $p < 0.05$ , \*\* $p < 0.01$  and \*\*\*\* $p < 0.0001$

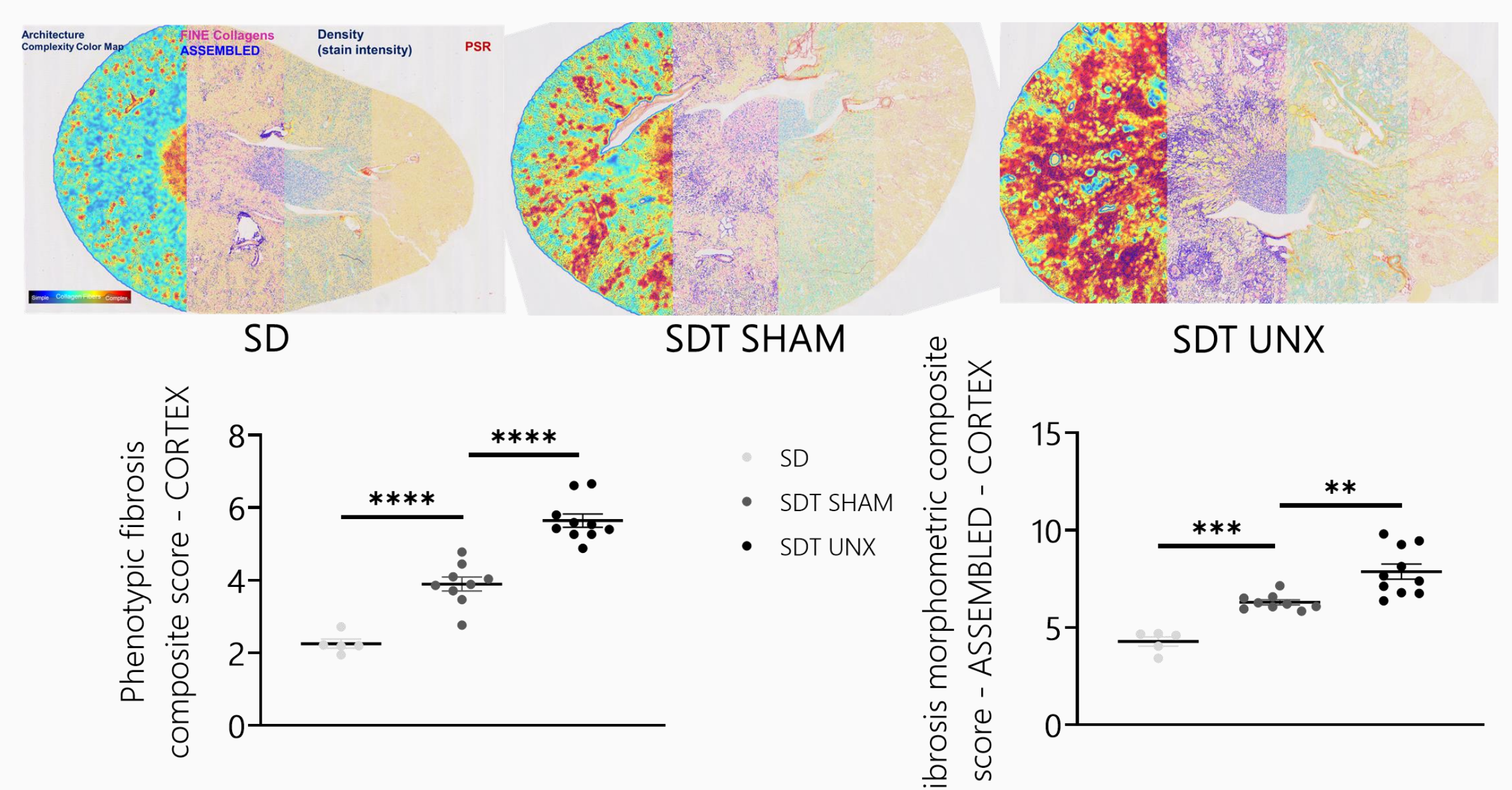
### 3 PEMP analysis reveals podocytes effacement in SDT fatty rats, aggravated by unilateral nephrectomy



Representative images of double staining for podocin/integrin  $\alpha 3$  and maximum intensity projection with color coding for depth (left panel); Filtration Slit Length (FSL) and Filtration Slit Density (FSD) determined by PEMP (right panel) in SD rats, sham or Unx SDT fatty rats.

\* $p < 0.05$ , \*\* $p < 0.01$ , and \*\*\*\* $p < 0.0001$

### 4 FibroNest platform demonstrates the significant increase in phenotypic fibrosis composite scores in Unx SDT fatty rats



Representative pictures showing the panels illustrating original Sirius Red images and image analysis layers (upper panel), and phenotypic fibrosis composite scores (lower panel) assessed with PharmaNest's high resolution quantitative digital pathology in SD rats, sham or Unx SDT fatty rats.

\*\* $p < 0.01$ , \*\*\* $p < 0.001$  and \*\*\*\* $p < 0.0001$

## CONCLUSION

Our data demonstrate that unilateral nephrectomy with 0.3% salt diet in SDT fatty rats severely impairs kidney function and aggravates kidney lesions, including podocyte effacement and renal fibrosis within 10 weeks. This type 2 diabetic rat model should be useful to evaluate drugs targeting diabetic kidney disease.